Pulmonary Lesion Boundary Detection from an Endobronchial Ultrasonogram Using Polar Sector Maximum Intensity

Wannapon Suraworachet and Rajalida Lipikorn
Machine Intelligence and Multimedia Information Technology (MIMIT) Laboratory, Department of Mathematics and Computer Science, Faculty of Science, Chulalongkorn University, Bangkok, Thailand
Email: wannapon.s@gmail.com, rajalida.l@chula.ac.th

Anan Wattanathum
Pulmonary and Critical Care Division, Department of Medicine, Phramongkutklao Hospital, Bangkok, Thailand
Email: wattanathum_anan@hotmail.com

***Abstract*—This paper presents a method to detect pulmonary boundary from an endobronchial ultrasonogram which can automatically assist bronchoscopists to define the region of interests within obtained endobronchial ultrasonograms images in order to perform further texture analysis aiming to diagnose the lesion. Multiple image processing techniques are performed to capture lesion boundary, starting from transforming image pixels from Cartesian coordinates into Polar coordinates, iterating over each degree to find pixels with the highest intensity, grouping candidate pixels with Density-Based Spatial Clustering of Applications with Noise (DBSCAN), eliminating isolate groups by second order derivatives, smoothing an image using moving average filtering, connecting remaining pixels to form a boundary using cubic spline interpolation. The total of 200 images, which composed of 100 benign and 100 malignant images, are used to evaluate the proposed method. As a result, the correlation between the obtained boundary and the ground-truth data is 93.92%.**

***Index Terms*—boundary detection, endobronchial ultrasound, DBSCAN, moving average filter, cubic spline interpolation, polar system**

I. Introduction

Lung cancer is known as the major cause of death worldwide due to its high mortality rate [1]. The prompt screening of risky patients can help decrease the rate of mortality down by 80% [2] because small tumors are mostly identified as an infection or scar tissues, but not as cancer [3].

In order to diagnose pulmonary nodules, bronchoscopy with transbronchial lung biopsy (TBLB) is recommended due to its efficiency, especially when guided by endobronchial ultrasound (EBUS). EBUS is inserted via bronchoscope to actively visualize internal textures of lesions, which can provide the diagnosis yield of 60-80% [4]-[6], higher than conventional CT localization [5] or fluoroscopy, which can expose patients to harmful radiation [4], [7].

Apart from the benefits of EBUS visualization, the characteristics of EBUS image also have a correlation with the histopathology of the lesions. According to Kurimoto and colleagues, their study reveals that 92% of lesions with homogeneous pattern are benign, whereas 99 % of lesions with heterogeneous pattern are malignant [8]. In addition, the results from another research show that the presence of at least two out of three features of echoic patterns in EBUS image including heterogeneous pattern, continuous margin and the absence of a linear-discrete air bronchogram represents the malignancy of the lesions [9]. All these findings can possibly be a breakthrough to innovate a computer-aided diagnosis system and thus, lower the amount of biopsy and the pathology examination time for diagnosing further pulmonary lesions.

According to [10], an average examination time for bronchoscopy is 26.6 minutes, which results in 39,900 possible images due to video frame rate of 25-frame per second. Selection of the best frame or image for representing lesion features is significant for diagnostic and further process. Since the best representative frame is considered to have the largest lesion region among others, boundary detection is thus essential in order to calculate the lesion area to select a representative frame.

Moreover, boundary detection is useful for identifying continuous or non-continuous margin, which is one of the key features to classify benign and malignant lesions. Additionally, other crucial features including homogeneous or heterogeneous pattern and absence or presence of air bronchogram are required to firstly identify region of interests before measurement.

Various algorithms for detecting boundary have been proposed for ultrasound images used in different organs and tissues of human body, especially, in breast and prostate. However, there is no recent study on detecting lesion boundary from EBUS. Since EBUS image is captured within a lesion using mechanical radial

Manuscript received February 20, 2014; revised July 23, 2015.

doi: 10.18178/ijeee.4.2.185-188

ultrasound miniature probes, the perspective of lesion is not similar to other types of ultrasound images which are mostly coronal views deriving from curvilinear ultrasound probes. Therefore, in order to make use of these distinct EBUS image characteristics, a novel algorithm to detect the boundary of pulmonary lesion of an EBUS image with optimum accuracy is proposed in this paper to further adapt an efficient pulmonary lesion classification system.

For clarity of presentation, this paper is divided into four sections. Section 2 and 3 describe proposed methodology and experimental results, respectively. Finally, Section 4 presents discussion and conclusions.

II. Proposed Methodology

A. Preprocessing

Sample images that were captured randomly from endobronchial ultrasound video, are converted to gray scale. After that, each image is cropped to eliminate irrelevant components such as metadata written on the screen, leaving only an actual image to be processed as shown in Fig. 1.

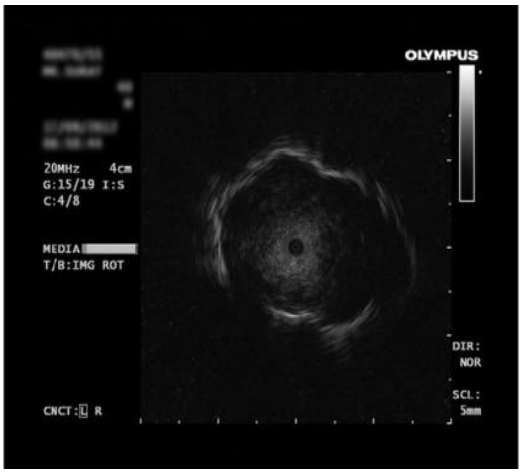

(a)

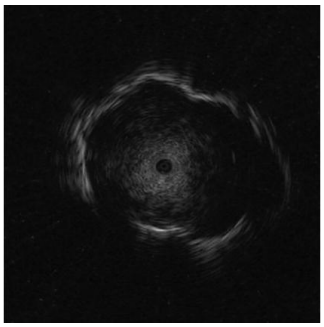

(b)

Figure 1. Image (a) before and (b) after preprocessing

B. Polar Sector Maximum Intensity

1) 360-Degree iterative maximum intensity detection

Each pixel of an image is transformed from Cartesian coordinates (x, y) into polar coordinates (radius, theta) by firstly assigning the central pixel of an image as the origin of the polar system. Then, an image is divided into 360 sectors according to the degree of theta. Regarding echogenicity of the boundary, the actual boundary tends to have hyperechoic characteristics. Thus, a pixel with maximum intensity of each sector is selected as a candidate pixel. If there are two or more pixels having the same maximum intensity, the innermost pixel or the pixel with the shortest radius is selected. After the candidate pixels of all sectors are obtained, the new origin of the polar system is calculated from these candidate pixels. Next, the process of finding a pixel with maximum intensity of each sector is iterated again until the new origin is stable or is the same as the previous origin. As a result, the final candidate pixels are illustrated in Fig. 2(a).

2) Density-Based spatial clustering of applications with noise (DBSCAN) iteration

After acquired all candidate pixels, these pixels have to be identified whether they are part of a lesion boundary or not by using Density-Based Spatial Clustering of Applications with Noise (DBSCAN), which was proposed by [11], as a clustering method to divide them into clusters. Assuming that the minimum number of points to form a cluster is 10; otherwise, they are considered as noise. Each cluster forms a boundary segment. By heuristic evaluation, 10 pixels are minor enough to separate coordinates into consecutive boundary segments, and major enough to consider a high density group of coordinates as another segment, but not to recognize them as noise. Then, statistical data of individual clusters, including standard deviation of segments' radius, are calculated. DBSCAN is iterated over a cluster that has a standard deviation of radius higher than 10. If all clusters have their standard deviation of radius lower than 10 or they are highly coherent which cannot be subdivided any further, this process terminates. Fig. 2(b) depicts a sample result of iteration over DBSCAN. Each cluster is labelled by different color and marker specifier.

3) Second order derivatives

In order to eliminate clusters that do not belong to a boundary, but are actually noise with high intensity, second order derivatives of local mean radius of each cluster is used and can be calculated according to (1). If there is any cluster, whose second order derivatives of local mean radius is higher than the mean radius among three considering consecutive clusters and also has the local mean intensity lower than the global mean intensity, it will be removed. The result after performing elimination by second order derivative is shown in Fig. 2(c).

$$f''(x) = f(x-1) + f(x+1) - 2\big(f(x)\big) \quad (1)$$

where x=1, 2, ..nth clusters,

n is the number of clusters arranged by theta,
$f(x)$ is the average radius of xth cluster,
$f(x-1)$ is the average radius of $(x-1)$th cluster,
$f(x+1)$ is the average radius of $(x+1)$th cluster,
$f''(x)$ is the second order derivative of cluster xth.

4) Polar coordinate system reference adjustment

After eliminating noise, the position in polar coordinate (radius, theta) of each remaining pixel is recalculated according to the new reference which is the center of an image, not the unstable center as in 2.2.1. In

order to be consistent and to make a comparison across all data, the center of reference or the origin of polar system should be the same which is at the image center.

5) Smoothing by moving average filter

Next, the remaining pixels are smoothed using moving average filter [12] with a span of nine in order to filter out noise spikes and make the boundary to be less fluctuated, revealing only significant pixels of boundary.

6) Cubic spline interpolation

Finally, all of the pixels are reconnected to each other while the missing representative pixels are estimated by cubic spline interpolation with theta (x) and radius (y) as the input data. Consequently, a spline function is used to estimate the unknown radii to match with the given thetas in a specific range of -180 to 180 degree. The result of this process is demonstrated in Fig. 2(d).

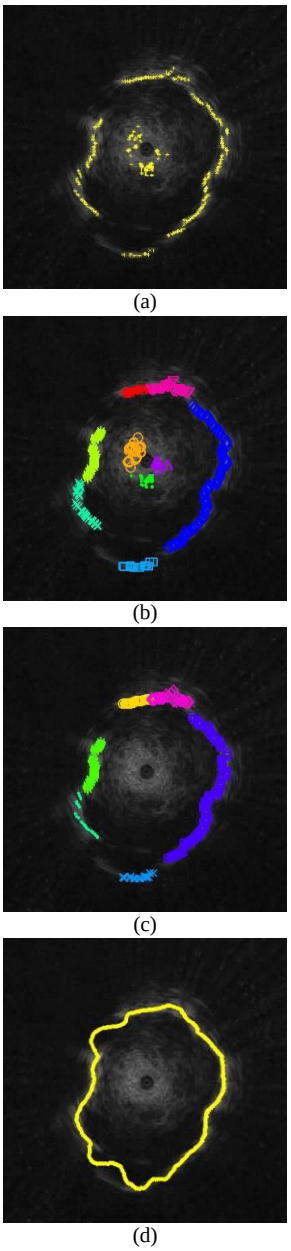

Figure 2. (a) The result of 360-degree iterative maximum intensity detection(b) the result of DBSCAN iteration(c) the result of elimination by second order derivatives(d) the final result of proposed boundary detection

III. Experimental Results

Input data are video files, which are recorded during endobronchial ultrasonography and collected from Phramongkutklao Hospital, Bangkok, Thailand. The data are composed of 10 samples of benign and 10 samples of malignant lesions. Additionally, the video file format is MPEG-1 with a dimension of 576×720 pixels or 288×352 pixels, and was captured at frame rate of 25 frames per second. Ten frames are randomly selected from each file. Hence, there are 200 images in total for undergoing the proposed boundary detection.

To evaluate the proposed method, the boundaries obtained from the proposed method are compared to the ground truth data degree-by-degree by calculating the correlation of x,y and the radius which measures from the center of an image. The results show that the detected boundaries from the proposed method are correlated with the actual boundary by 93.92%. The overlap of detected boundaries from two methods is shown in Fig. 3. The yellow solid line illustrates the boundary obtained from our proposed method whereas the red dashed line represents the ground truth boundary.

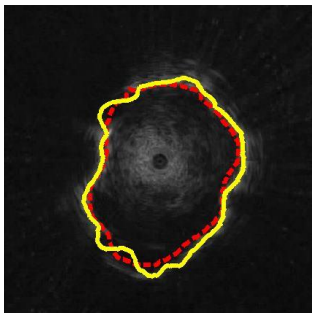

Figure 3. Overlapping of the boundaries obtained from the proposed method (yellow solid line) and the ground truth data (red dashed line)

Additionally, the study shows that there is not much difference in correlation between benign and malignant lesion data. According to Table I, the correlation of benign lesion is 93.88% while malignant is 93.96% which yield the total correlation of 93.92%.

TABLE I. Correlation of Boundary of the Proposed Method and Ground Truth Data Categorized by Lesion Types

Benign	Malignant	Total
0.9388	0.9396	0.9392

IV. Discussion and Conclusions

In summary, this paper proposes a new method to detect the boundary of a lesion which includes polar system transformation, maximum intensity localization, DBSCAN clustering, second order derivatives, smoothing and spline interpolation, to briefly delineate lesion boundary from sample EBUS images. As a result, automatic pulmonary lesion boundary detection from EBUS images is performed successfully and hence can assist radiologists in further process. However, there are some special cases of EBUS images which cause the detection some problems, and hence, result in lower correlation with ground truth data, such as images with

highly presence of air linear bronchogram, as illustrated in Fig. 4(a), and mostly absence of lesion margin as depicted in Fig. 4(b). For the highly presence of air bronchogram, the texture inside lesion is non-uniform and hyperechoic which is difficult to distinguish between boundary and air bronchogram, whereas, in mostly absence of lesion margin, more than 50% of lesion boundary disappear, due to an inappropriate frame selection. Thus, further study may be required to solve these problems. In addition, the study of EBUS images and their defined boundaries will be continued in order to distinguish benign from malignant lesions by considering their ultrasonographic features. Finally, a computer-aided diagnosis (CAD) of lung cancer can be constructed.

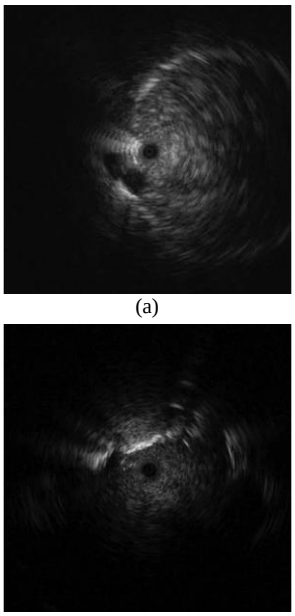

(a)

(b)

Figure 4. EBUS image with (a) highly presence of air linear bronchogram (b) mostly absence of lesion margin

ACKNOWLEDGEMENTS

This project is financially supported by Centre of Excellence in Mathematics (CEM), Thailand, and the authors are grateful to Phramongkutklao Hospital, Bangkok, Thailand, for providing all endobronchial ultrasonographic data.

REFERENCES

[1] J. Ferlay, *et al*. (2013). GLOBOCAN 2012 v1.0, Cancer incidence and mortality worldwide: IARC cancer base No. 11. *International Agency for Research on Cancer*. [Online]. Available: http://globocan.iarc.fr

[2] D. R. Aberle, *et al.*, "Reduced lung-cancer mortality with low-dose computed tomographic screening," *New England Journal of Medicine*, vol. 365, no. 5, pp. 395-409, Aug. 2011.

[3] American College of Chest Physicians. (2004). What if I have a spot on my lung? Do I have cancer? *Patient Education Guide*. [Online]. Available: http://onebreath.org/document.doc?id=36

[4] F. J. Herth, A. Ernst, and H. D. Becker, "Endobronchial ultrasound-guided transbronchial lung biopsy in solitary pulmonary nodules and peripheral lesions," *European Respiratory Journal*, vol. 20, no. 4, pp. 972-974, Oct. 2002.

[5] M. C. Yang, *et al*., "Diagnostic value of endobronchial ultrasound-guided transbronchial lung biopsy in peripheral lung cancers," *Journal of the Formosan Medical Association*, vol. 103, no. 2, pp. 124-129, Feb. 2004.

[6] S. M. Lin, *et al.*, "Diagnostic value of endobronchial ultrasonography for pulmonary tuberculosis," *Journal of Thoracic and Cardiovascular Surgery*, vol. 138, no. 1, pp. 179-84, Jul. 2009.

[7] T. Shirakawa, *et al.*, "Usefulness of endobronchial ultrasonography for transbronchial lung biopsies of peripheral lung lesions," *Respiration*, vol. 71, no. 3, pp. 260-268, May-Jun. 2004.

[8] N. Kurimoto, M. Murayama, S. Yoshioka, and T. Nishisaka, "Analysis of the internal structure of peripheral pulmonary lesions using endobronchial ultrasonography," *CHEST Journal*, vol. 122, no. 6, pp. 1887-1894, Dec. 2002.

[9] C. H. Kuo, S. M. Lin, H. C. Chen, C. L. Chou, C. T. Yu, and H. P. Kuo, "Diagnosis of peripheral lung cancer with three echoic features via endobronchial ultrasound," *CHEST Journal*, vol. 132, no. 3, pp. 922-929, Sep. 2007.

[10] N. Shinagawa, *et al.*, "Transbronchial biopsy for peripheral pulmonary lesions under real-time endobronchial ultrasonographic guidance," *Journal of Bronchology & Interventional Pulmonology*, vol. 16, no. 4, pp. 261-265, Oct. 2009.

[11] M. Ester, H. P. Kriegel, J. Sander, and X. Xu, "A density-based algorithm for discovering clusters in large spatial databases with noise," in *Proc. Second International Conference on Knowledge Discovery and Data Mining*, 1996, pp. 226-231.

[12] S. W. Smith, *Digital Signal Processing: A Practical Guide for Engineers and Scientists*, Massachusetts: Newnes, 2003, ch. 15, pp. 277-284.

Wannapon Suraworachet received the Bachelor of Science in computer science and the Master of Science in computer science and information technology from Chulalongkorn University, Bangkok, Thailand in 2011 and 2014, respectively.

Her previous research interest included human-website interactions within Facebook through Facebook-commerce. In 2012, she was a research student in Machine Intelligence and Multimedia Information Technology (MIMIT) Laboratory, Department of Mathematic and Computer Science, Chulalongkorn University, Bangkok, Thailand, where she was engaged in medical image processing project. Her current research interests focused on image processing, image segmentation, feature extraction and classification, especially in medical imaging.